

CASE SUMMARY

Canine, thermal burns



Case Courtesy of:
Dr. Jeanette Pettit, Peticote Veterinary Clinic, Southampton, NJ

Signalment: Canine, 3 y/o, F, Beagle

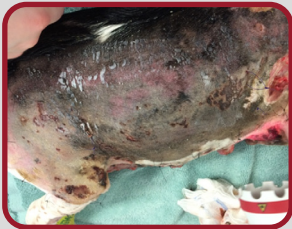
History: April was burned in a kennel fire while her owners were away from home. The neighbor rescued April from her kennel.

Diagnostics and Exam Findings: Initial exam revealed a 4X4 inch alopecic area on the left lateral hip with mild erythema. April re-presented six days later with foul smelling drainage noted from blistered skin on her flank.

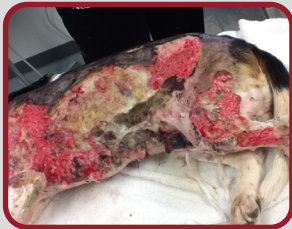Laser Treatment Details: 4,200 joules to entire affected area at an energy density of 6 J/cm².

Frequency of Treatment: Daily during bandage changes initially, then every other day.

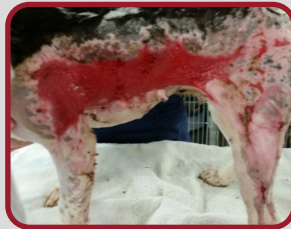Other Treatments: Started antibiotics and analgesics at initial exam. Wet to dry bandages, wound lavage, silver sulfadiazine ointment, enrofloxacin, buprenorphine and tramadol were used during treatment.



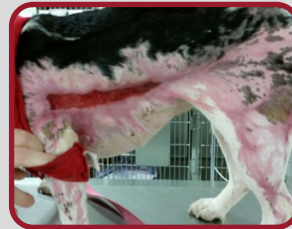Day 6



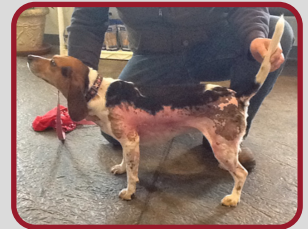Day 12



Day 26



Day 51



After 3 months of treatment