

CASE SUMMARY

Canine, severe necrotizing wound



Case Courtesy of:

Dr. Jeffrey W. Foltz, Dover Veterinary Clinic, Dover OH

Signalment: Canine, 8 y/o, MN, Labrador Retriever

History: Owner noted partial weight bearing lameness and severe swelling in the left front leg. The patient had a history of chasing the family cat three days prior when the owner assumed the dog had slipped on the floor. A family member recalled seeing the cat bite the dog and that the cat had bitten another family member previously, resulting in hospitalization for treatment of "a rare bacteria".

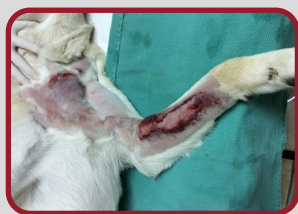Diagnostics and Exam Findings: Initial exam and radiographs revealed soft tissue swelling and pain on flexion and extension of the left elbow. 72 hours later re-presented; now febrile with evidence of a wound with severe tissue devitalization and avascular necrosis. Additional swelling was noted in the ventrolateral neck area.

Laser Treatment Details: Applied 4-5 J/cm² over the affected area.

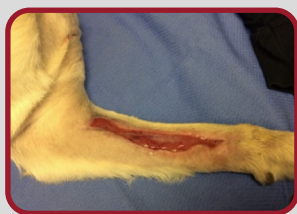Frequency of Treatment: 21 laser treatments over 7 weeks.

Other Treatments: The wound was surgically debrided. Antibiotics and analgesics were used, and wound care was followed.

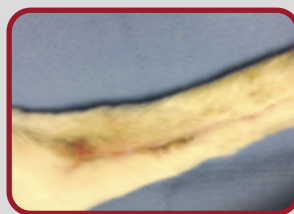
Comments: Staff noted minimal drainage from the wound and a lack of any putrid odor during bandage changes. Edema within the leg and neck resolved within days of starting laser treatment. The patient was comfortable and did not bother or chew his bandage and the wounds healed rapidly with minimal scarring.



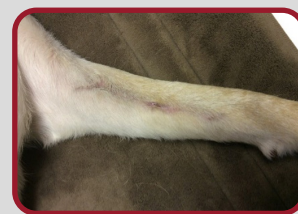Presentation



Day 20



Day 43



1 month post treatment